

Protein losing enteropathy in Yorkshire Terriers – Retrospective study in 31 dogs

D. BOTA¹, A. LECOINDRE², A. POUJADE³, M. CHEVALIER⁴, P. LECOINDRE², F. BAPTISTA⁵, E. GOMES¹, J. HERNANDEZ^{1*}

¹ Centre Hospitalier Vétérinaire Fregis, 43 av. Aristide Briand, 94110 Arcueil, France

² Clinique des Cerisiez, Route de Saint-Symphorien-d'Ozon 69800 Saint-Priest France

³ Laboratoire d'Anatomie Pathologique Vétérinaire du Sud-Ouest, 129, route de Blagnac 31201 Toulouse cedex 2, France

⁴ Laboratoire Biomnis, 17/19 avenue Tony Garnier, 69007 Lyon, France

⁵ StemCell2Max Biocant Park Nucleo 04, Lote 02 3060-197 Cantanhede Portugal

*Corresponding author: jhernandez@fregis.com

SUMMARY

Yorkshire Terriers are reportedly predisposed to PLE. The aim of our retrospective study was to describe the clinical, laboratory, ultrasonographic, endoscopic and histological findings of Yorkshire Terriers with PLE and to compare potential prognostic factors to those recently published. A retrospective study was performed using clinical reports from two private practices in France from 2010-2012. For each case, the age, sex, clinical signs, serum albumin, abdominal ultrasound findings, gross endoscopic appearance, histopathological reports, and outcome at 1 month and 1 year were recorded. Females were over-represented (20/31). The sole clinical finding in more than 40% of cases was ascites. Hyperechoic striations were frequently seen on abdominal ultrasound (16/25). Multiple white villi on gross endoscopic examination was observed in all the 22 dogs with intestinal lymphangiectasia on histopathology. Lacteal and crypt dilation were common histopathological lesions (24/31 and 27/31 cases, respectively). Yorkshire Terriers are susceptible to a potentially severe form of PLE characterized by abdominal effusion due to hypoalbuminaemia, and histologically by crypt lesions, lacteal dilation, and inflammation. The absence of diarrhoea cannot be used to rule out PLE. Abdominal ultrasound and gross endoscopy appearance are useful for detecting intestinal lymphangiectasia. Outcome is variable and some dogs completely fail to respond to therapy.

Keywords : Crypt dilation, lymphangiectasia, protein losing enteropathy, Yorkshire Terrier

RESUME

Entéropathie exsudative chez le Yorkshire Terrier – Étude retrospective de 31 cas

Selon la littérature, les Yorkshire Terriers sont prédisposés au développement d'entéropathies exsudatives. Le but de notre étude rétrospective est de décrire les caractéristiques cliniques, de laboratoire, échographiques, endoscopiques et histologiques de cas d'entéropathies exsudatives chez le Yorkshire Terrier et de comparer les facteurs pronostiques à ceux récemment publiés. L'étude a été réalisée en utilisant les dossiers médicaux issus de 2 centres privés de référés en France de 2010 à 2012. Pour chaque cas, l'âge, le sexe, les signes cliniques, l'albuminémie, les observations échographiques, l'aspect endoscopique duodénal, les lésions histologiques intestinales ainsi que l'évolution à 1 mois et à 1 an ont été analysés. Les femelles sont surreprésentées (20/31). L'ascite est l'observation clinique la plus fréquente (40% des cas). Des striations hyperéchogènes dans la muqueuse intestinale grêle sont fréquemment observées au cours de l'examen échographique (16/25). Des villosités blanchâtres ont été observées au cours de l'examen endoscopique sur tous les cas où une lymphangiectasie intestinale a été identifiée à l'examen histopathologique (22 cas). La dilatation des chylifères et des cryptes intestinales est une observation histologique fréquente (24 et 27 cas respectivement). Les Yorkshire Terriers présentent une forme potentiellement grave d'entéropathie exsudative caractérisée par des épanchements cavitaires liée à l'hypoalbuminémie et histologiquement par une dilatation des chylifères et des cryptes intestinales et de l'inflammation. L'absence de diarrhée ne peut être utilisée pour exclure la maladie. L'examen échographique et l'endoscopie sont des examens efficaces permettant d'identifier les lésions de lymphangiectasie. L'évolution des Yorkshire Terriers atteints est variable avec quelques chiens qui ne répondent pas au traitement.

Mots-clés : Dilatation des cryptes intestinales, lymphangiectasie, entéropathie exsudative, Yorkshire Terrier

Introduction

Protein-losing enteropathy (PLE) is caused by a group of intestinal pathologies that are responsible for nonselective protein loss resulting in hypoproteinaemia [12]. Common causes of PLE are inflammatory bowel disease (IBD), intestinal lymphoma, and intestinal lymphangiectasia (IL) [4]. Intestinal infectious diseases, gastrointestinal haemorrhage, and intestinal crypt lesions may also induce PLE [4].

Clinical signs of PLE include diarrhoea, vomiting, weight loss, abdominal distension secondary to ascites and/or

peripheral oedema, dyspnoea secondary to pleural effusion or pulmonary thrombosis, and muscle tremors and seizure activity due to hypocalcaemia and hypomagnesaemia [4, 5, 9]. Diagnosis involves identification of hypoalbuminaemia, exclusion of renal protein loss by urinalysis and urine protein-to-creatinine ratio, and exclusion of hepatic dysfunction by normal pre and post-prandial serum bile acids. Detection of enteric protein loss by measuring faecal α 1-proteinase inhibitor is not routinely performed [10]. Hyperechoic intestinal mucosal striations on ultrasound are described as highly specific for lacteal dilation [6]. Ultimately, intestinal biopsies are needed to identify gastrointestinal histopathologic lesions that define the underlying aetiology of the PLE [7].

Yorkshire Terriers are reportedly predisposed to PLE, being ten times more likely to contract the disease than other breeds [4]. Recently, clinical features, intestinal histopathology, and outcome were described in a retrospective study of 30 Yorkshire Terriers [12]. Females were overrepresented. A third of the dogs in this study did not have a history of diarrhoea. Predictors of death within 4 months of diagnosis were a history of vomiting, monocytosis, low BUN, degree of hypoalbuminaemia, and intestinal villous blunting.

The aim of our retrospective study was to describe the clinical, laboratory, ultrasonographic, endoscopic, histological findings, treatment and outcome of Yorkshire Terriers with PLE and to compare potential prognostic factors to those recently published.

Material and Methods

Medical records from two referral practices in France (Centre Hospitalier Vétérinaire Frégis (CHVF), and the Clinique Vétérinaire des Cerisiez (CVC)) were reviewed for Yorkshire Terriers diagnosed with PLE from January 2010 to January 2012.

The inclusion criteria were as follows: Yorkshire Terriers with hypoalbuminemia < 25 g/l (reference range for albumin 30-40 g/l), urine dipstick negative for proteinuria or urine protein-to-creatinine ratio < 0.5, normal pre and post prandial serum bile acids, and histopathological intestinal lesions characteristic of diseases recognised to cause PLE. All dogs must have had a negative faecal flotation test within 1 month of presentation or been treated for intestinal parasites before presentation. Dogs with evidence of protein-losing nephropathy or impaired liver function were excluded. Dogs with gastrointestinal parasites or haemorrhage, parvovirus infection, neoplasia, and those that had received glucocorticoids or other immunosuppressive treatment within 2 weeks of the intestinal biopsy were excluded. Cases where tissue biopsy depth was inadequate for assessing intestinal crypts were also excluded.

Clinical information collected for each dog included: age, sex, previous treatment, physical examination findings (namely the presence/absence of diarrhoea and abdominal distension), serum total protein and albumin at admission, abdominal ultrasonographic findings, histopathological lesions and treatment.

A board-certified radiologist reviewed all available captured static images of abdominal ultrasound studies. Endoscopy was performed using an Olympus GIF-180 and biopsies using disposable "alligator swing-jaw fenestrated" (2.45 mm) biopsy forceps. The minimum number of biopsies taken per segment was 6. Histopathologic evaluation was based upon review of all endoscopic biopsies under the recommendations of the World Small Animal Veterinary Association Gastrointestinal Standardization Group (2008) by 2 pathologists (AP and MC) [1]. The slides were relabelled

using a random study number and both pathologists reviewed all the slides. Each pathologist was blinded to the original histopathology results and to any clinical information. A standard form was completed for each dog, including quality, morphologic features (villous stunting, epithelial injury, crypt lesion, lacteal dilation, and mucosal fibrosis), and inflammation (intraepithelial lymphocytes, lamina propria lymphocytes and plasma cells, lamina propria eosinophils, lamina propria neutrophils and other). Inadequate biopsy quality was a criterion for exclusion. Morphological features and inflammation were graded as normal, mild, moderate, and marked. Diagnosis of intestinal lymphangiectasia was based on the pathologist's ability to constantly identify the lumen of dilated lacteals. Only cases with consensual final diagnoses between both pathologists were included.

Clinical signs and measurement of serum albumin at 1 month after discharge were recorded. All referring veterinarians or owners were contacted 1 year after diagnosis to determine the outcome (animal alive or deceased, albuminemia, with or without treatment).

Treatment options were different between the 2 centers. At the CHVF, all 19 dogs were started on a low-fat hyperdigestible diet (Hills i/D Low Fat® Sophia-Antipolis, France), metronidazole (Flagyl®, Sanofi-Aventis, Gentilly, France 15mg/kg twice daily), and prednisolone (Megasolone®, Merial, Lyon, France, 1-2 mg/kg/day). At the CVC, all 12 dogs were started on the same diet, metronidazole, prednisolone, ciclosporine (Atopica®, Novartis, Hünigues, France, 5 mg/kg/day), and marbofloxacin (Marbocyl®, Vetoquinol, Lure, France, 2mg/kg/day). These differences were only due to the different protocols used at each institution.

Statistical analysis

Statistical analysis was performed using SAS v. 9.1.3. (SAS Institute Inc., Cary, NC, USA). The descriptive statistical analysis was expressed as a mean \pm SD for age, sex, frequency for clinical signs, serum albumin, abdominal ultrasound findings, and histological lesions. Multivariate logistic regression analyses were used to determine the variables associated with outcome (alive or deceased) at 1 month and 1 year after diagnosis, respectively. The identification of the significant variables and interactions ($P < 0.05$) was performed by backward elimination.

The candidate explanatory variables were the following: sex (male/female), age (<5yrs/5-10yrs/>10yrs), clinical signs (presence or absence of vomiting, diarrhea, abdominal distention), ultrasound findings (presence or absence of small intestinal hyperechoic mucosal striations and/or ascites), histopathological findings (presence or absence of lymphangiectasia and/or crypt distension) and treatment (the use of steroids with and without ciclosporine) were determined as categorical variables, with serum albumin concentration as a continuous variable.

A Fisher's exact test was performed to test the association between: 1) treatment and albumin at 1 month (≤ 15 g/l and > 15 g/l); 2) treatment and histopathological findings and 3) treatment and ultrasound findings. The identification of the significant variables and interactions ($P < 0.05$) was performed by backward elimination. Statistical significance was set at a P -value < 0.05 .

Results

Medical records of 66 Yorkshire terriers with suspected PLE were reviewed. Nine dogs were excluded because of absence of intestinal biopsies. Fifteen dogs were excluded because of absence of serum bile acids test results or abnormal urine protein-to-creatinine ratios. Eleven dogs were excluded because of inadequate biopsy quality. A total of 31 dogs fulfilled the inclusion criteria. Nineteen dogs were diagnosed at the CHVF and 12 at the CVC.

CLINICAL FINDINGS

Descriptive results are presented in Table I. The mean age at presentation was 7.7 years \pm 3.0 years. Twenty dogs were females and 11 were males. Presenting complaints included small bowel diarrhoea (18), abdominal distension (13), and vomiting (6). Median duration of clinical signs before presentation was 1 month (3 days-6 months). Previous medications included maropitant, loperamide, and antibiotics (cefovexin, marbofloxacin, metronidazole). Physical examination revealed abdominal distension consistent with ascites in 13 dogs. Dyspnoea and/or muffled lung sounds were not recorded in any of the dogs. One dog presented with signs of dehydration and one with peripheral ventral oedema.

LABORATORY FINDINGS

Abnormal leucograms were rare: 1 dog had a mild mature neutrophilia and 2 dogs had thrombocytosis.

Hypoglobulinaemia (reference range 15-35 g/l) was found in 6/31 dogs (Table II).

Cholesterol was measured in 12 dogs and was below the reference range in 10 dogs (reference range 125-300 mg/dl, median 93.47 mg/dl). Serum total calcium was measured in 12 dogs and was low in all the dogs (reference range 9-11.5 mg/dl) serum ionized calcium concentrations were not measured in any of the dogs. Clinical signs compatible with hypocalcaemia (tremors, tetany, seizures) were not reported in any of the cases. Cobalamin was measured in 12 dogs and hypocobalaminemia was found in 3 dogs (reference range 200-600 ug/ml).

ABDOMINAL ULTRASOUND FINDINGS

Abdominal ultrasonography was performed in 25 dogs. Small intestinal hyperechoic mucosal striations were visible

in 16 animals. Fourteen animals had ascites and small intestinal hyper echoic striations on abdominal ultrasound. Other intestinal ultrasonographic findings included mucosal speckling in 8 dogs, increased intestinal wall thickness in 5 dogs and reduced intestinal peristalsis in 2 dogs.

A strong association was found between the presence of hyper echoic striation on ultrasound lesions and the presence of intestinal lymphangiectasia on histopathology ($p=0.02$).

UPPER GASTROINTESTINAL ENDOSCOPY

Duodenal endoscopy was performed in all 31 dogs. Abnormalities affecting the duodenal mucosa included friability in 25 dogs and multiple white villi in 22 dogs. All this 22 dogs had confirmed lymphangiectasia on histopathology.

GASTROINTESTINAL HISTOPATHOLOGY

Intestinal biopsies were obtained from all 31 dogs by intestinal endoscopy. The mean number of duodenal biopsies was 7. Tissue quality was classified as adequate in all cases (Tables III-V).

Lacteal dilation was identified in 24 and was classified as mild in 20 and moderate in 4 dogs (Fig. 1). Crypt dilation was identified in 27 and classified as mild in 19 dogs, moderate in 6, and marked in 2 dogs (Fig. 2). The presence of lacteal dilation on histopathology was strongly associated with an albumin at admission of < 15 g/l ($p=0.02$). Lymphoplasmacytic inflammation was detected within the lamina propria of 27 dogs. Only 2 dogs had some degree of neutrophilic inflammation.

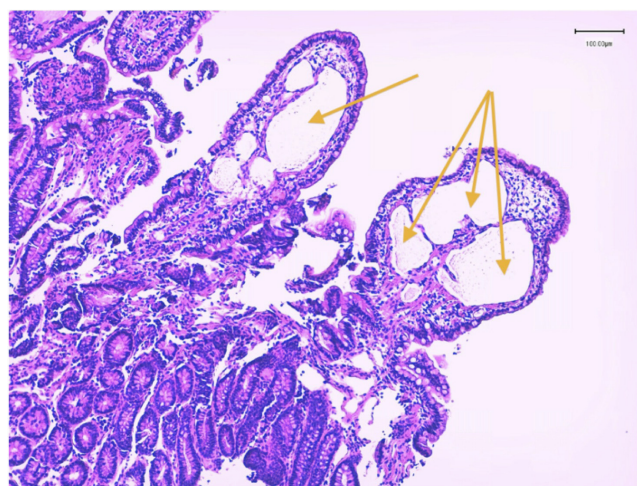


FIGURE 1: Dilated lacteal vessels (arrow). Hematoxylin and Eosin stain. 40X. Courtesy of Dr Poujade, LAPVSO.

Dog	Sex	Age	Diarrhea	Ascites	Albumin	AUS	Lymph.	Cryptitis	F. up
1	FS	7	+	-	19	+	+	+	
2	F	9	-	+	14	-	+	-	
3	F	8	-	+	18	+	+	+	
4	FS	6	+	+	13	-	+	-	
5	M	4	+	-	18	-	+	+	D
6	F	5	+	+	12	-	-	+	LFU
7	F	4	+	+	15	+	-	+	
8	M	2	-	+	10	-	-	+	
9	F	6	+	-	23	-	-	+	
10	F	8	+	+	7	+	+	-	
11	M	8	+	+	9	-	+	+	D
12	MC	11	+	-	23	+	+	+	
13	MC	14	+	-	18	-	-	+	D
14	FS	11	+	+	19	-	+	+	D
15	M	3	+	+	14	-	+	+	D
16	F	8	-	+	15	+	+	+	
17	FS	10	-	+	8	+	+	+	
18	M	7	+	+	12	+	+	-	
19	M	4	-	+	10	+	+	+	
20	F	13	-	+	10	-	+	+	
21	F	7	-	+	7	-	-	+	
22	F	10	-	+	14	+	-	+	D
23	F	12	+	+	6	+	+	+	
24	F	5	+	+	8	+	+	+	D
25	F	6	-	+	8	-	+	+	D
26	M	7	-	+	12	-	+	+	
27	M	11	+	+	12	-	+	+	
28	F	7	-	+	7	+	+	+	
29	M	8	-	+	10	+	+	+	D
30	F	8	+	+	7	+	+	+	D
31	F	11	+	+	9	+	+	+	

F female; M male; + present; - absent; AUS abdominal ultrasound; Lymph lymphangiectasia; Cryp cryptitis; F. up follow up after 1 year. LFU - lost to follow up;

TABLE I: Results for age, clinical signs, albumin at admission, presence of hyperechoic mucosal striations on abdominal ultrasound, presence of lymphangiectasia and/or cryptitis on histopathology and follow up (dead or alive).

Variable	Median (for all dogs)	Median (CHVF/CVC)	Range (CHVF / CVC)
Albumin (RR 30-40 g/l)	12.4 g/l	14.5 g/l (CHVF) 9.0 g/l (CVC)	8-23 (CHVF) 7-14 (CVC)

TABLE II: Albumin variation between the 2 practices (CHVF/CVC)¹.

¹ CHVF Centre Hospitalier Vétérinaire Frégis; CVC: Clinique Vétérinaire des Cerisioz
PLE Protein Loosing Enteropathy

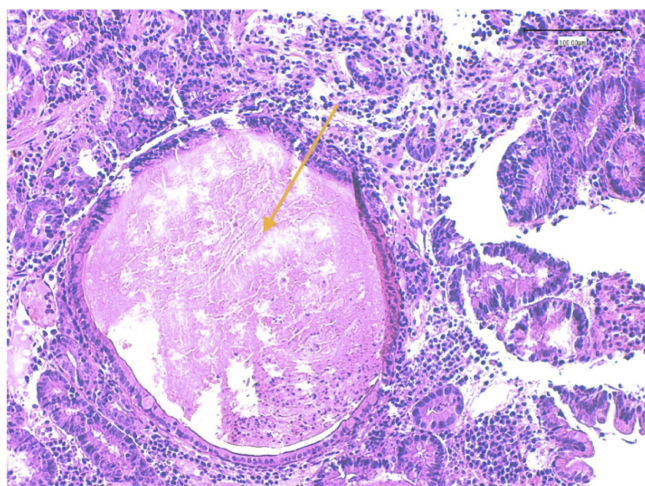


FIGURE 2: Intestinal crypt distension (arrow). Hematoxylin and Eosin stain. 40X. Courtesy of Dr Poujade, LAPVSO.

TREATMENT

Treatment options were different between the 2 centers. At the CHVF, all 19 dogs were started on a low-fat hyperdigestible diet metronidazole and prednisolone. Ciclosporine was added to the treatment in 4 dogs where treatment did not control clinical signs. At the CVC, all 12 dogs were started on the same low-fat hyperdigestible diet, metronidazole, prednisolone, ciclosporine and marbofloxacin. These differences were only due to the different protocol used at each institution.

Clinical signs, serum albumin concentration, abdominal ultrasound findings and histopathology results did not statistically differ between the 2 treatment groups.

Other initial therapies included colloid perfusion (8) and vitamin B12 injections (3). The increase on albumin at 1 month (> 20 g/L) was strongly correlated with the use of prednisolone and metronidazole alone ($p=0,004$), compared to the use of prednisolone, ciclosporine, metronidazole and marbofloxacin.

OUTCOME

Clinical signs, abdominal ultrasound findings, gastrointestinal histopathology results, and serum albumin at admission and at 1 month were not correlated with the outcome at 1 year.

At 1 month, 2/31 dogs had died, 3 were lost to follow-up, and 26 were re-evaluated. Six of those 26 dogs had an albumin of less than or equal to 15 g/l, and 20 had an albumin concentration of more than 15 g/l.

At 1 year, 10/31 dogs had died. Four dogs died within 2 months, 4 dogs died between 2 and 6 months, and 2 dogs died between 6 month and 1 year after diagnosis. Eighteen dogs were alive at the time of writing with a median survival

of >18 months. Reasons for euthanasia included: fungal osteomyelitis (1), signs related to the enteropathy (diarrhoea, weight loss, ascites) (6), suspected lymphoma (1), and pleural effusion (1). One dog died of unknown causes. The dog with fungal osteomyelitis had been living on the Ivory Coast and had received prednisolone (0.5mg/kg/d) and ciclosporine (5mg/kg/d). Among the 6 dogs that were euthanized for causes related to the disease, 1 dog developed hypocalcaemia (total calcium 36 mg/dl, RR: 90-120) and seizures, and was euthanized. The remaining five continued to show clinical signs despite medical treatment and the owners elected for euthanasia. Detailed histopathology from these 6 dogs is presented in Table VI. One dog was diagnosed with pleural effusion and the owner requested euthanasia without performing further examination. One dog was euthanized one year after diagnosis with persistent GI signs and ultrasonographic findings compatible with multicentric lymphoma (weight loss, vomiting, diarrhoea, thickened small intestine and lymph node enlargement at abdominal ultrasound) but the diagnosis could not be confirmed. One dog (number 15) discontinued treatment for 6 months and similar clinical signs recurred: diarrhoea and abdominal distention due to ascites. Hypoalbuminaemia was present (18 g/l) and upper GI endoscopy revealed similar lesions to those found previously. Histopathologic lesions were unchanged (lymphoplasmacytic inflammation with lacteal dilation and crypt lesions).

There was no statistically significant difference between mortality at 1 month and at 1 year in dogs with lymphangiectasia and/or crypt lesions ($p>0.05$).

DISCUSSION

This study reports the clinical, ultrasonographic, endoscopic, clinicopathological, and GI histopathological findings of 31 Yorkshire Terriers with a diagnosis of PLE. Yorkshire Terriers of all age groups were affected with a predominance of females. Small bowel diarrhoea and abdominal distension due to ascites were common clinical findings. Near 50% of the dogs in this study did not have a history of diarrhoea. Therefore, PLE should not be excluded in Yorkshire terriers without diarrhoea. Vomiting was less frequent than in a previous study and it was not identified as a negative prognostic indicator [12].

Outcome and survival varied widely: some dogs achieved prolonged survival and remission of clinical signs, whereas others failed to respond. More than 50% of dogs with long-term follow-up had a prolonged response to treatment with complete resolution of clinical signs. In Simmeron's study [12], predictors of death within 4 months of diagnosis were a history of vomiting, monocytosis, low BUN, degree of hypoalbuminemia, and intestinal villous blunting. In this study, none of the studied variables was identified as a prognostic indicator. There was a strong association between albumin > 20 g/l at 1 month and the use of prednisolone and metronidazole alone, compared to the use of prednisolone

	Villous stunting	Epithelial injury	Crypt dilation	Lacteal dilation	Mucosal fibrosis
Normal	12 (4/8)	8 (3/5)	4 (0/4)	7 (2/6)	27 (9/18)
Mild	16 (6/10)	23 (8/15)	19 (8/11)	20 (7/13)	4 (2/2)
Moderate	3 (1/2)	0	6 (3/3)	4 (2/2)	0
Marked	0	0	2 (0/2)	0	0

TABLE III: Morphologic changes identified on duodenal mucosa of Yorkshire terrier with PLE (CVC/CHVF)

	Intraepithelial lymphocytes	Lamina propria lymphocytes and plasma cells	Lamina propria eosinophils	Lamina propria neutrophils	Other
Normal	6 (2/4)	0	30 (10/20)	29 (9/20)	30 (10/20)
Mild	21 (7/14)	14 (5/9)	1 (1/0)	2 (2/0)	1 (1/0)
Moderate	3 (1/2)	16 (6/10)	0	0	0
Marked	1 (1/0)	1 (0/1)	0	0	0

TABLE IV: Types and degrees of inflammatory cells identified on duodenal mucosa of Yorkshire terrier with PLE (number of cases at CVC/ numberr of cases at CHVF)

Normal tissue	0
Lymphoplasmocytic inflammation	31 (11/20)
Eosinophilic inflammation	0
Neutrophilic inflammation	2 (2/0)
Lymphangiectasia	24 (9/15)
Mucosal atrophy/fibrosis (non inflammatory)	0
Other : crypt dilation	27 (11/16)

TABLE V: Final histopathologic diagnosis (number of cases at CVC/ number of cases at CHVF)

Dog	VS	EI	CD	LD	MF	IL	LpLP	LpE	LpN
14	0	+	+	++	0	+	+	0	0
15	0	+	+	+	0	+	++	0	0
22	0	+	+	0	0	0	+	0	0
24	+	+	+++	+++	0	+++	++	0	+
25	0	+	+	++	0	+	++	0	0
30	+	+	++	+	0	+	++	0	0

VS villous stunting; EI epithelial injury; CD crypt distention; LD lacteal dilation; MF mucosal fibrosis; IL intraepithelial lymphocytes; LpLP lamina propria lymphocytes and plasma cells; LpE lamina propria eosinophils; LpN lamina propria neutrophils; normal = 0; mild = + ; moderate = ++; marked = +++

TABLE VI : Morphologic features and inflammation identified on duodenal mucosa from Yorkshire terrier who died from causes related to the disease.

and metronidazole combined with ciclosporine and marbofloxacin ($p=0.004$). The impact of this higher albuminaemia at 1 month in the CHVF group on survival could not be established.

There was a strong correlation between the presence of hyperechoic mucosal striations on ultrasound and the presence of intestinal lymphangiectasia on histopathology ($p=0.02$). This finding has been reliably associated with PLE in dogs and could be used as an indicator of intestinal protein losses in cases of hypoalbuminaemia in Yorkshire terriers [13]. Only 2 dogs with hyperechoic mucosal striations did not show intestinal lymphangiectasia on duodenal histopathology. This may be due to the heterogeneity of lacteal dilation distribution within the mucosal layer.

All dogs with multiple white villi on gross endoscopic evaluation of duodenal mucosa were confirmed to have intestinal lymphangiectasia on histopathology.

Hypocalcaemia and hypomagnesaemia have been described in Yorkshire terriers with PLE [5]. Poor intestinal absorption of vitamin D and calcium, loss of vitamin D binding protein and increased leakage of calcium and magnesium into the intestinal lumen are the main suspected reasons for this. In this study, only 12/31 animals underwent total serum calcium analysis. All 12 dogs were found to have low total calcium although only 1 dog developed clinical signs compatible with hypocalcaemia (seizures). Unfortunately, measurement of ionized calcium was not available.

Crypt dilation was present in 27/31 dogs and lacteal dilation in 24/31 dogs. More than 20% of the dogs in this study lacked lymphatic dilation. Therefore, PLE in Yorkshire Terriers may be a more complex disease than previously thought. Intestinal lymphangiectasia in this breed may be due to another underlying pathology. Simmeron hypothesized that crypt lesions could be the primary lesions but, in this study, lymphangiectasia and crypt lesions (crypt distension) coexisted in only two thirds of cases [12]. Inflammation is another potential initiating lesion. Sample bias introduced by endoscopic biopsies and regional distribution of lesions is possible. Quality bias is less likely as only cases with adequate biopsy quality were included in this study.

Crypt lesions are much more common in this study than in previous reports [8]. This may be due to improved biopsy technique over time. It has been suggested that crypt dilation is not associated with bacterial colonization in this breed [1]. The lack of association between outcome and the use of marbofloxacin argues in favour of a non-septic origin. It has been hypothesised that crypt lesions represent a degenerative process and it is not known whether they are a cause of PLE or markers of another underlying lesion.

The limitations of this study include its retrospective nature and the lack of uniformity in blood work and follow-up. For instances, video or images of the scoping were not

reviewed and it could be part of the limitations. Other limitation of the study is the absence of ileum biopsies. Despite the fact that these dogs had small intestinal diarrhea, only upper gastro intestinal endoscopy was performed and none had lower gastro intestinal endoscopy. The lack of ileal biopsies may have introduced bias on the severity of the disease and distribution of the lesions. Treatment protocols could not be compared, as allocation was not randomized. In this study, treatment options were a board certified internal medicine specialist decision. Other protocols are also described in literature and should be considered in this breed as well: a recent study in dogs with PLE [2] showed that a chlorambucil-prednisolone protocol was efficient in treating these animals.

In conclusion, Yorkshire terriers are susceptible to a potentially severe form of PLE characterized by abdominal effusion due to hypoalbuminaemia, and histologically by crypt lesions, lymphangiectasia, and inflammation. Females are over-represented. The absence of diarrhoea cannot be used to rule out PLE. Abdominal ultrasound and gross endoscopy appearance are useful for detecting intestinal lymphangiectasia. Outcome is variable and some dogs completely fail to respond to therapy.

References

1. - CRAVEN M., DUHAMEL G.E., SUTTER N.B. and SIMPSON K.W.: Absence of bacterial association in Yorkshire Terriers with protein-losing enteropathy and cystic intestinal crypts. *J. Vet. Intern. Med.*, 2009, **23**, 757.
2. - DANDRIEUX J.R., NOBLE P.J.M., SCASE T.J., CRIPPS P.J., GERMAN A.J.: Comparison of a chlorambucil-prednisolone combination with an azathioprine-prednisolone combination for treatment of chronic enteropathy with concurrent protein-losing enteropathy in dogs: 27 cases (2007-2010). *J. Am. Vet. Med. Assoc.*, 2013, **242**, 1705-14.
3. - DAY M.J., BILZER T., MANSELL J., WILCOCK B., HALL E.J., JERGENS A., MINAMI T., WILLARD M., WASHABAU R., World Small Animal Veterinary Association Gastrointestinal Standardization Group.: Histopathological standards for the diagnosis of gastrointestinal inflammation in endoscopic biopsy samples from the dog and cat: a report from the World Small Animal Veterinary Association Gastrointestinal Standardization Group. *J. Comp. Pathol.*, 2008, **138** Suppl 1: S1-S43.
4. - DOSSIN O., LAVOUE R.: Protein-losing enteropathies in dogs. *Vet. Clin. North Am. Small Anim. Pract.*, 2011, **41**, 399-418.
5. - KIMMEL S.E., WADDELL L.S., MICHEL K.E.: Hypomagnesemia and hypocalcemia associated with protein-losing enteropathy in Yorkshire terriers: five cases (1992-1998). *J. Am. Vet. Med. Assoc.*, 2000, **217**, 703-706.

6. - KULL P.A., HESS R.S., CRAIG L.E., SAUNDERS H.M., WASHABAU R.J.: Clinical, clinicopathologic, radiographic, and ultrasonographic characteristics of intestinal lymphangiectasia in dogs: 17 cases (1996- 1998). *J. Am. Vet. Med. Assoc.*, 2001, **219**, 197–202.
7. - LARSON R.N., GINN J.A., BELL C.M., DAVIS M.J., FOY D.S.: Duodenal endoscopic findings and histopathologic confirmation of intestinal lymphangiectasia in dogs. *J. Vet. Intern. Med.*, 2012, **26**, 1087–1092.
8. - LECOINDRE P., CHEVALLIER M., GUERRET S.: Protein-losing enteropathy of non neoplastic origin in the dog: a retrospective study of 34 cases. *Schweiz. Arch. Für Tierheilkd.*, 2010, **152**, 141–146.
9. - MELLAMBY R.J., MELLOR P.J., ROULOIS A., BAINES E.A., MEE A.P., BERRY J.L., HERRTAGE M.E.: Hypocalcaemia associated with low serum vitamin D metabolite concentrations in two dogs with protein-losing enteropathies. *J. Small Anim. Pract.*, 2005., **46**, 345–351.
10. - MURPHY K.F., GERMAN A.J., RUAUX C.G., STEINER J.M., WILLIAMS D.A., HALL E.J.: Fecal alpha1-proteinase inhibitor concentration in dogs with chronic gastrointestinal disease. *Vet. Clin. Pathol.*, 2003, **32**, 67–72.
11. - PETERSON P.B., WILLARD M.D.: Protein-losing enteropathies. *Vet. Clin. North Am. Small Anim. Pract.*, 2003, **33**, 1061–1082.
12. - SIMMERSONS.M., ARMSTRONG P.J., WUNSCHMANN A., JESSEN C.R., CREWS L.J., WASHABAU R.J.: Clinical features, intestinal histopathology, and outcome in protein-losing enteropathy in Yorkshire Terrier dogs. *J. Vet. Intern. Med.*, 2014, **28**, 331–337.
13. - SUTHERLAND-SMITH J., PENNINCK D.G., KEATING J.H., WEBSTER C.R.L.: Ultrasonographic intestinal hyperechoic mucosal striations in dogs are associated with lacteal dilation. *Vet. Radiol. Ultrasound.*, 2007, **48**, 51–57.