

## Case Report

# Cutaneous metastases of a bronchial adenocarcinoma in a cat

CLAUDE FAVROT\* and FREDERIQUE DEGORCE-RUBIALES†

\*Dermatology Unit, Clinic for Small Animal Internal Medicine, Vetsuisse Faculty, University of Zürich, Winterthurerstrasse 260, 8057 Zürich, Switzerland †Laboratoire Vétérinaire du Sud-Ouest, 129, Route de Blagnac, 31201 Toulouse Cedex, France

(Received 30 July 2004; accepted 24 January 2005)

**Abstract** This case report describes a cat with metastasis of a bronchial adenocarcinoma to the abdominal skin. The cat had been treated with antibiotics and corticosteroids for several episodes of coughing when it acutely developed erythema, pustules and plaques on the abdominal skin. Diagnosis was based on cytological examination of fine-needle aspirates of cutaneous pustules, X-ray examination of the thorax and histological examination of skin biopsy samples. As the prognosis was poor, the cat was euthanased. Necropsy findings confirmed the diagnosis. Cutaneous metastases of lung carcinoma are rare in cats but have been reported in the digits with underlying bone involvement. To the authors' knowledge, this is the first report of metastasis of a feline bronchial carcinoma to the ventral skin.

## INTRODUCTION

Cutaneous metastases of internal tumours are rare in cats<sup>1</sup> and have been reported in association with mammary adenocarcinoma and digestive and respiratory tract carcinoma.<sup>2–9</sup> Pulmonary carcinoma with digital metastasis also involving bone has been described by several authors and is the most common cause of tumour metastasis to the skin in cats.<sup>3–6,8,10–14</sup> Cutaneous metastases may be the first sign of an undiagnosed visceral malignancy, and their recognition may allow rapid diagnosis of this type of cancer.<sup>6</sup> This case report describes metastasis of a bronchial adenocarcinoma to the abdominal skin in a cat.

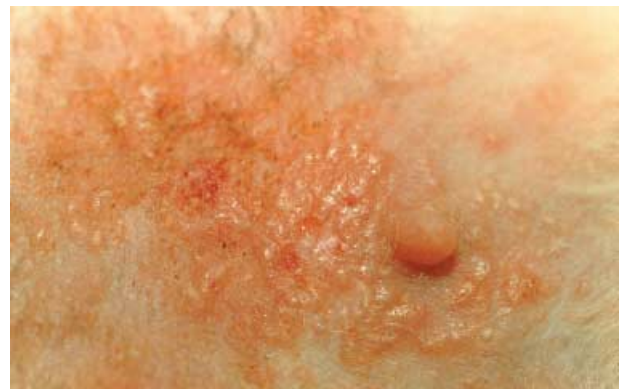## CASE REPORT

An 11-year-old, spayed female, Domestic Short Hair cat (4.5 kg) was presented for evaluation of anorexia, abdominal papular dermatitis and intermittent lameness. The cat had been treated 5 weeks prior to referral for coughing and fever with cephalexin 20 mg/kg (Cefalexine, Virbac) orally twice daily and prednisolone 1 mg/kg (Megasolone, Merial) orally once daily for 10 days. Treatment resulted in cessation of coughing. During the 12 months prior to referral, the cat had had several episodes of coughing, and a presumptive diagnosis of asthma was made. The symptoms were successfully treated with intramuscular injections of

methylprednisolone 10 mg once monthly for three treatments (Vetacortyl, Vetoquinol).

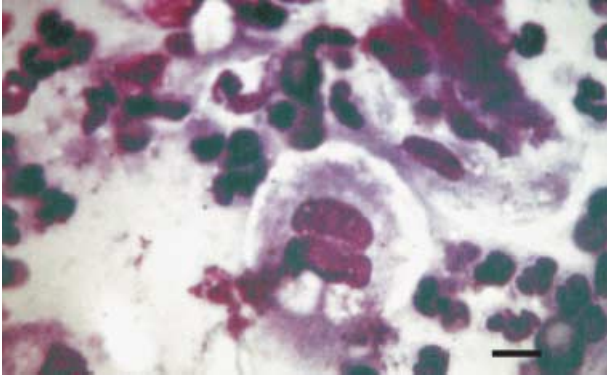
On physical examination, the cat was depressed and febrile (39.7 °C). Auscultation of the thorax revealed bilateral pulmonary rales, originating mainly from the diaphragmatic lobes. A bilaterally symmetric distribution of erythematous papules and pustules was seen on the abdomen. The lesions were centred on the areolae of the mammary glands. The papules sometimes coalesced to form erythematous plaques (Fig. 1). The lesions were painful. The popliteal lymph nodes were also painful and enlarged. Lameness was not apparent during the physical examination but the cat was reluctant to move, and palpation of both limbs was painful.

Cytological examination of a fine-needle aspirate from an intact pustule revealed inflammatory cells and numerous round to polyhedral cells, which varied in size, had vacuolated foamy cytoplasm and large nuclei with large, irregular-shaped nucleoli. These cells were seen throughout the sample, sometimes in clusters.



**Figure 1.** View of the abdomen showing plaques and pustules centred on the areolae of the mammary glands.

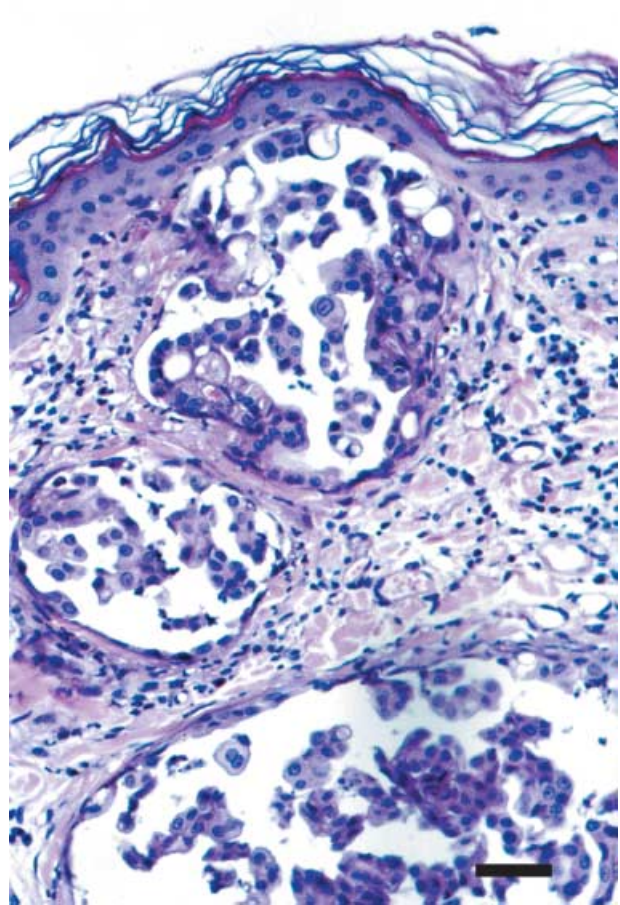
Correspondence: Claude Favrot, Dermatology Unit, Clinic for Small Animal Internal Medicine, Vetsuisse Faculty, University of Zürich, Winterthurerstrasse 260, 8057 Zürich, Switzerland.  
E-mail: cfavrot@vetclinics.unizh.ch



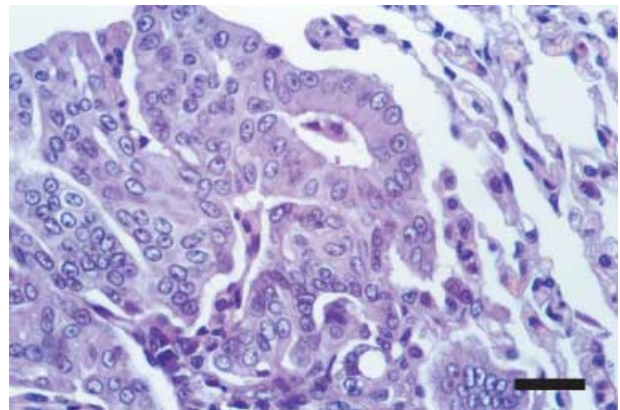
**Figure 2.** Fine-needle aspirate of a pustule of the same cat: a multinucleated carcinomatous cell is present. (Diff-Quik staining  $\times 400$ ) Bar = 15  $\mu\text{m}$ .

Some of the cells were multinucleated (Fig. 2). Normal and abnormal mitotic figures were seen and some cells had cilia. These cells were identified as neoplastic epithelial cells. The cilia suggested a respiratory tract origin. Lymph node cytology indicated reactive hyperplasia without evidence of metastasis. The results of a complete blood cell count and biochemistry panel were within the normal ranges and an enzyme-linked immunosorbant assay (ELISA) for feline leukaemia virus (FeLV) and feline immunodeficiency virus (FIV) antigens was negative. X-Ray examination of the thorax showed diffuse increased density of the lungs in an alveolar pattern with consolidation of the right diaphragmatic lung lobe. Histopathological examination of biopsy samples of the abdominal skin revealed cords and nodules of neoplastic epithelial cells in the superficial and deep dermis (Fig. 3). There was marked anisocaryosis and moderate mitotic activity. Emboli of these cells were also present in the lymphatics. Based on these findings, a tentative diagnosis of cutaneous metastases of a bronchial carcinoma was made. As the prognosis was poor, the owners elected for euthanasia.

Necropsy findings included generalized pulmonary congestion, numerous small white nodules, with an average diameter of 1–2 mm, disseminated in the pulmonary parenchyma and a larger nodule (1.5 cm) in the right diaphragmatic lung lobe. Similar small nodules were also seen on the parietal pleura. Except for the cutaneous tumours and enlarged popliteal lymph nodes, no other abnormalities were found at necropsy. Samples of pleura, pulmonary parenchyma, and bronchial and popliteal lymph nodes were examined histologically. Most of the bronchi and pulmonary vessels contained proliferative epithelial tissue, which was composed of cells that were cuboidal to columnar with foamy cytoplasm and round vesicular nuclei (Fig. 4). There was moderate mitotic activity and some cells had cilia. Similar lesions were observed in samples of pleura. Reactive hyperplasia was the only change seen in samples of lymph nodes. A diagnosis of cutaneous and pleural metastases of bronchial adenocarcinoma was made.



**Figure 3.** Histopathology of skin showing lymphatic invasion of groups of atypical cells with anisocaryosis. (Haematoxylin & eosin staining  $\times 200$ ) Bar = 15  $\mu\text{m}$ .



**Figure 4.** Histopathology of the lung showing irregular tubular arrangement of atypical epithelial cells. (Haematoxylin & eosin staining  $\times 400$ ) Bar = 25  $\mu\text{m}$ .

## DISCUSSION

Primary pulmonary neoplasms are rare in cats; most (85%) are adenocarcinomas.<sup>15</sup> In cats, malignant pulmonary tumours frequently metastasize, particularly to the regional lymph nodes, pleura, mediastinum,

bones, muscles, heart, brain and spleen.<sup>10</sup> It has been suggested that this distribution is due to direct arterial embolism of tumour cells from the lung.<sup>5</sup> Long bone and vertebral metastases of bronchial carcinoma have been reported in cats and are more common than metastases to the skin.<sup>11,12</sup> The most common site is the digits where there may be skin as well as bone involvement.<sup>1,4,6,11</sup> There does not appear to be a preferential site for cutaneous metastases of bronchial carcinoma in humans;<sup>16</sup> however, subungueal metastases are frequent.<sup>17</sup>

Cutaneous metastases are considered rare in dogs and cats;<sup>1–4</sup> most are carcinomas.<sup>18</sup> In humans, overall incidence (calculated on the basis of the total number of cancer patients observed) of cutaneous metastasis is 5.3%.<sup>19</sup> In cats, information about cutaneous metastases stems from individual case reports<sup>2,3,11</sup> and the majority recorded are digital metastases of bronchial carcinoma.<sup>4,6,15</sup>

Feline patients with bronchial carcinomas frequently present with cutaneous lesions as the first symptom encountered.<sup>5,11</sup> However, this cat had respiratory signs weeks to months before the cutaneous lesions. In humans and cats, bronchial carcinoma cutaneous metastases usually consist of one or several nodules.<sup>16</sup> The metastases in this case clinically resembled primary dermatitis, which has been previously described for cutaneous metastases of feline mammary adenocarcinoma<sup>2</sup> and in human mammary ductal carcinomas (Paget's disease).<sup>20,21</sup>

Enlargement of the popliteal and bronchial lymph nodes was not associated with neoplastic emboli. Van der Linde-Sipman & van den Ingh<sup>11</sup> suggested that feline pulmonary carcinoma metastasizes haematogenously rather than lymphogenously but dermal lymphatic invasion was seen. Both haematogenous and lymphatic metastatic spread can occur simultaneously.

Pulmonary carcinoma has been reported to metastasize to muscle in cats, and in one report, lameness was the main complaint on presentation.<sup>22,23</sup> The cat in our case had lameness as a major presenting complaint but the post-mortem examination did not reveal metastasis to the muscle. Such metastasis may, however, have been overlooked and the bone marrow was not examined for metastases. It seems unlikely that the pain observed in this case was caused by the lymph node enlargement.

In this case, many criteria suggestive of malignancy<sup>24</sup> were present in the aspirated cells: pleomorphism, anisocaryosis, increased mitotic activity, multinucleation and large nucleoli. The round to polyhedral shape of the cells and the organization in clusters was indicative of an epithelial origin. Furthermore, the presence of cilia on some cells suggested a respiratory origin for the primary tumour. The prognosis of bronchial carcinoma with distant metastasis is poor in cats.<sup>11</sup> In humans, the treatment of choice is surgical excision because most of the metastases are solitary nodules.<sup>17</sup> Surgical excision was not possible in this case because of the extent of the lesions.

## REFERENCES

1. Scott DW, Miller WH, Griffin CE. Neoplastic and non-neoplastic tumors. In: Scott DW, Miller WH, Griffin CE eds. *Kirk and Muller's Small Animal Dermatology*. Philadelphia: W.B. Saunders, 2001: 1236–413.
2. White SD, Carpenter JL. Cutaneous metastases of a mammary adenocarcinoma resembling eosinophilic plaques in a cat. *Feline Practice* 1985; 15: 27–9.
3. Jacobs TM. The lung-digit syndrome in a cat. *Feline Practice* 1997; 25: 31–6.
4. Muller A, Guaguère E, Devauchelle P. Métastases cutanées chez les carnivores domestiques. *Pratique Médicale et Chirurgicale de l'Animal de Compagnie* 1998; 33: 267–81.
5. May C, Newsholme SJ. Metastasis of feline pulmonary carcinoma presenting as multiple digital swelling. *Journal of Small Animal Practice* 1989; 30: 302–10.
6. Estrada M, Lagadic M. Métastases digitales d'un carcinoma pulmonaire asymptomatique chez le chat: Etude d'une série de 11 cas. *Pratique Médicale et Chirurgicale de l'Animal Compagnie* 1992; 27: 791–5.
7. Hahn KA, McEntee MF. Primary lung tumors in cats: 86 cases. *Journal of the American Veterinary Medicine Association* 1997; 211: 1257–60.
8. Gottfried SD, Popovitch CA, Goldschmidt MH et al. Metastatic digital carcinoma in the cat: a retrospective study of 36 cats (1992–98). *Journal of the American Animal Hospital Association* 2000; 36: 501–9.
9. Crowe DT, Todoroff RJ. Umbilical masses and discoloration as signs of intra-abdominal disease. *Journal of the American Animal Hospital Association* 1982; 18: 295–8.
10. Barr IF, Gruffydd-Jones TJ, Brown PJ. Primary lung tumors in the cat. *Journal of Small Animal Practice* 1987; 28: 1115–25.
11. van der Linde-Sipman JS, van den Ingh TS. Primary and metastatic carcinomas in the digits of cats. *Veterinary Quarterly* 2000; 22: 141–5.
12. Gustafsson P, Wolfe D. Bone metastasizing lung carcinoma in a cat. *Cornell Veterinarian* 1968; 58: 425–30.
13. Jensen HE, Arnbjerg J. Bone metastasis of undifferentiated pulmonary adenocarcinoma in a cat. *Nordisk Veterinärmedicin* 1986; 38: 288–97.
14. Pool RR, Bodle J, Mantos JJ et al. Primary lung carcinoma with skeletal metastases in the cat. *Feline Practice* 1974; 4: 36–41.
15. Fox LE, King RR. Cancers of the respiratory system. In: Morrisson WB ed. *Cancer in Dogs and Cats. Medical and Surgical Management*. Jackson, WY: Teton New-Media, 2001: 497–512.
16. Ambrogi V, Nofroni I, Tonini G et al. Skin metastases in lung cancer: analysis of a 10-year experience. *Oncology Reports* 2001; 8: 57–61.
17. Cohen PR. Metastatic tumors to the nail unit: subungual metastases. *Dermatological Surgery* 2001; 27: 280–93.
18. Yager JA, Wilcock BP. Tumors metastatic to the skin. In: Yager JA, Wilcock BP eds. *Color Atlas and Text of Surgical Pathology of the Dog and Cat. Dermatopathology and Skin Tumors*. London: Wolfe, 1994: 309–10.
19. Krathen RA, Orengo IF, Rosen T. Cutaneous metastasis: a meta-analysis of data. *Southern Medical Journal* 2003; 96: 164–7.
20. Cohen PR. Skin clues to primary and metastatic malignancy. *American Family Physician* 1995; 51: 1199–204.

21. Osther PJ, Balslev E, Blichert-Toft M. Paget's disease of the nipple. A continuing enigma. *Acta Chirurgica Scandinavica* 1990; 156: 343–52.
22. Moore AS, Middleton DJ. Pulmonary adenocarcinoma in three cats with non-respiratory signs only. *Journal of Small Animal Practice* 1982; 23: 501–9.
23. Schmitz JA, Bailey DE, Bailey RE. Bronchogenic carcinoma in a cat presenting as rear leg lameness. *Feline Practice* 1978; 8: 18–21.
24. Alleman RA, Bain PJ. Diagnosing neoplasia: the cytologic criteria for malignancy. *Veterinary Medicine* 2000; 204–41.
25. Hager CM, Cohen PR. Cutaneous lesions of metastatic visceral malignancy mimicking pyogenic granuloma. *Cancer Investigation* 1999; 17: 385–90.

**Résumé** Cet article décrit un chat présentant des métastases d'adénocarcinome bronchique sur la peau de l'abdomen. Le chat a été traité avec des antibiotiques et des corticoïdes pour plusieurs épisodes de toux, lorsqu'il a présenté un érythème, des pustules et des plaques sur la peau de l'abdomen. L'examen cytologique d'aspiration de pustules cutanées, l'examen radiographique du thorax et l'examen histopathologique de biopsies cutanées ont permis le diagnostic. Le chat a été euthanasié, du fait du mauvais pronostic. L'autopsie a confirmé le diagnostic. Les métastases cutanées des carcinomes pulmonaires sont rares chez le chat, mais sont bien décrites au niveau des doigts, avec une atteinte osseuse. A la connaissance des auteurs, il s'agit du premier cas de métastase de carcinome bronchique à la peau du ventre.

**Resumen** Este informe describe un gato con metástasis de un adenocarcinoma bronquial a la piel abdominal. El gato había sido tratado con antibióticos y corticoesteroides durante varios episodios de tos, cuando desarrolló un eritema agudo, pústulas y placas en la piel abdominal. El diagnóstico se basó en el examen citológico mediante aspiración con aguja fina de pústulas cutáneas, en el examen radiográfico del tórax y en el examen histológico de muestras de biopsia cutáneas. Teniendo en cuenta el grave pronóstico, el gato fue eutanasiado. Los resultados de la necropsia confirmaron el diagnóstico. Las metástasis cutáneas del carcinoma pulmonar son raras en gatos pero se han descrito en los dígitos con la implicación subyacente del hueso. Según nuestros conocimientos, éste es el primer informe de metástasis de un carcinoma bronquial felino a la piel ventral.

**Zusammenfassung** Dieser Bericht beschreibt eine Katze mit Metastasen eines bronchialen Adenocarcinoms in der abdominalen Haut. Die Katze wurde wegen mehrerer Episoden von Husten mit Antibiotika und Kortikosteroiden behandelt, als sie akut Erythem, Pusteln und Plaques auf der abdominalen Haut entwickelte. Die Diagnose basierte auf zytologischer Untersuchung von Feinnadelaspiraten kutaner Pusteln, Röntgenuntersuchung des Thorax und histologischer Untersuchung von Hautbiopsien. Da die Prognose schlecht war, wurde die Katze euthanasiert. Eine Autopsie bestätigte die Diagnose. Kutane Metastasen von Lungenkarzinomen bei der Katze sind selten, wurden aber in den Zehen mit zugrundeliegender Knochenbeteiligung beschrieben. Nach Wissen der Autoren ist dies der erste Bericht über Metastasen eines felinen Bronchialkarzinoms in ventraler Haut.